

Case Report Instructions EMSAVM / MASVM Neurology

General instructions

- Case reports, written in prose, must be in a problem-oriented approach and include a complete presentation of the case, illustrations where available and a short discussion of the case with the current literature with references. Candidates must demonstrate a comprehensive understanding of the topic with assessing all obtained diagnostic test results.
- A case report should contain 2000 words +/- 10%, excluding tables, references and appendix. Case reports > 2400 words will automatically be denied (0 points) or sent back for rewriting.
- The 10 cases must be a mixture of various species, problems and diagnosis, all pertaining to the selected Master's program. Candidates are required to keep a table of the already submitted cases which shall be send with each new case report submission. The ESAVS Office will provide an Excel template for the table below:

Case Nr.	Species	Problem/s	Diagnosis
----------	---------	-----------	-----------

- Candidates are advised to submit cases shortly after beginning and throughout the program and not all cases at the end of the program.
- ESAVS cannot guarantee the evaluation of more than 3 case reports per semester. To ensure an evaluation in a specific semester, reports should be submitted no later than the given deadline for the respective semester (please see [Important Dates](#) on the ESAVS website).

Cases should be set out under the following headings:

- Title
- Signalement
- Case History and physical Examination
- Neurological examination including definition of the neuroanatomical localization of the lesion
- Case assessment including complete problem list, differential diagnosis with likelihood of what is possible for the case, tests performed and interpretation of these in relation to the case – do not use bullet points but write in prose
- Diagnosis
- Treatment (drugs need exact dosages) and adequate follow up
- Discussion of case in relation to current literature (no repetition of literature but a discussion why the case fits or does not fit what is known)
- References
- Appendix with laboratory results and diagnostic imaging pictures including interpretation (the examination board member reserves the right to see the original results (laboratory, diagnostic imaging) of selected cases)

Each case report is viewed by one member of the Examination Board and graded on a 0-20 scale (<10= fail, 10-11.9 = sufficient, 12-13.9 = fair, 14-15.9 = good, 16-17.9 = very good, 18-20 = excellent).

Evaluation of a case report

Step 1: Is the case report acceptable?

Is the case described in the report suitable at all? Reasons to reject a case are:

- A case is too simple (e.g. a dog with intervertebral disk extrusion, Hansen type I)
- Lack of adequate state of the art clinical tests to arrive at a diagnosis (or at least a presumptive diagnosis). The case could be resubmitted when the lacking information can be retrieved.
- A case is too complicated (e.g. rare degenerative disorder requiring many and complex investigations) to allow reasonable coverage within the given number of words.
- The animal's life was endangered by excessive/unnecessary diagnostic tests or treatments (including surgery). Such a case cannot be resubmitted.
- A case that falls not within the specified master program (e.g. a pure orthopedic case for the neurology master)
- Most diagnostic tests and interpretation are done by referring veterinarian
- Inadequate follow-up of case (e.g. diagnosis reached after euthanasia with no follow-up available)
- Multiple cases all with same problems or diagnosis (e.g. many cases with seizing and encephalitis in the Neurology Master Program)
- Cases not seen during the enrollment in the program of the master student or where the master student is not the primary responsible clinician.
- More than 2400 words.

If a case is rejected the case report is assigned 0 points. The reason will be stated in the evaluation.

Step 2: Grading of the accepted case report

The case report will be evaluated based on a check sheet

An accepted case starts with the maximum of 20 points. 10 points are minimally required as a passing grade.

The check sheet (see below) contains a list of 12 potential inadequacies. For each one the examiner can allocate a number of points. At the end a total number of points are given.

Recommendations for the candidate to avoid deduction of points:

- Make sure the history is sufficient (in an animal with seizures, be sure to ask about frequency, duration and kind of seizures; in an animal with paraparesis/plegia give information about the onset and duration, etc.).
- Give all details of the physical exam (report that rectal exam was done and normal in an animal with hypercalcaemia, etc.)
- Reported tests need to be relevant for the animal and interpretation needs to be concise and also relevant.
- Do not just give a list of all potential differentials, but explain why a differential might be more or less likely. Explain why you rule-out some differentials.
- Discuss your case – do not just repeat text book knowledge. If something has not been done or is abnormal and does not fit, try to explain this with pertinent literature.
- Show all results – missing graphics generally lead to points deducted.
- Treatment must be correct for the dog or cat – e.g. antibiotics only have to be given if there is a clear indication etc.).
- Give information about outcome and therapy. Be specific.

Case Report Evaluation Check Sheet / Neurology

Grading Criteria:

For students who have enrolled in a Master of Advanced Studies in Veterinary Medicine (MASVM) or European Master of Small Animal Veterinary Medicine (EMSVM) program **before the winter semester 2024-2025**, the following grading criteria apply:

- The grades of the individual case reports are averaged to obtain one single grade. When this average grade is **below 10**, candidates are requested to resubmit revised versions of the failed case reports or new cases.
- A case report may not be acceptable and may be rejected if critical concerns in one (or several) areas result in a fail, regardless of whether all other required criteria are adequately met.

For students who have enrolled in a Master of Advanced Studies in Veterinary Medicine (MASVM) program for the first time **from the winter semester 2024-2025 onwards**, the following **new** grading criteria apply:

- 1. Pass = 10 points and more
- 2. Fail (case report insufficient) = below 10 points
 - modifications required - resubmission possible
 - case report insufficient - 0 points resubmission of this case report not possible - a new case report needs to be submitted
- **IMPORTANT:** the **average grade** for the module must be **13 points or higher** and none of the case reports must be graded below 10 points.
- A case report may not be acceptable and may be rejected if critical concerns in one (or several) areas result in a fail, regardless of whether all other required criteria are adequately met

***The maximum grade of a case report is 20 points. The second column indicates the maximum number of points that can be reached.
In the third column the examiner indicates the number of achieved points, half points may also be allocated.***

	Maximum points	Allocated points
Complete signalment, history and physical examination <i>Comments:</i>	1	
Correct interpretation of clinical signs and definition of neuroanatomical localization <i>Comments:</i>	4	
Adequate differentials/ assessment for the problem list- the candidate tailors the differentials to this case and not every possible differential for each problem <i>Comments:</i>	2	
Adequate and/or appropriate tests (not too few or too many) <i>Comments:</i>	1	
Adequate assessment of test results (available results must be assessed for the submitted case) <i>Comments:</i>	1	
Diagnostic tests adequately graphically presented (radiographs, ECG, endoscopy, etc. must be shown in adequate quality and size) <i>Comments:</i>	2	
Correct and/or justified diagnosis <i>Comments:</i>	2	
Adequate or appropriate therapeutic management including generic drug names and dosages <i>Comments:</i>	2	
Adequate follow-up for the case report to be meaningful <i>Comments:</i>	1	
Discussion pertaining to submitted case, adequately referenced <i>Comments:</i>	2	
Language and word count adequate <i>Comments:</i>	1	
Special features not covered above <i>Comments:</i>	1	
TOTAL POINTS/ GRADE	20	

There is no “perfect” case and thus the attached example should be viewed more as how to present your case. If you have questions, please ask them during one of the courses early on – the course masters are ready and willing to help.

Case report 1

Candidate name:

Programme: Master programme neurology

Case report Number:

Date of submission:

Word count: 2130

Congenital hydrocephalus in a dog

Signalement:

A 7M old, male, 17.7 kg, mixed breed dog (Staffordshire bull terrier/ American Bulldog mix)

History:

The patient presented with a 3-month history of seizures. The owner had videotaped the seizures, and they were generalized tonic-clonic seizures, duration around 30 seconds. The seizures occurred every 3 weeks, and they came in clusters (more than one during a 24-hour period). Total seizure count was 20 since the first one was observed. In between seizure episodes, the owner perceived the dog as normal; eating and drinking normally, normal behavior, no learning difficulties. The dog was vaccinated and dewormed regularly and had never been abroad. The dog was currently not on any medication, had no history of trauma, and the seizures were unrelated to feeding times.

Physical examination:

Auscultation of the heart and lungs were normal. A normal respiratory rate (20/min) and heart rate (90/min) were measured. Mucous membranes were pink with a capillary refill time under 2 seconds. Abdominal palpation and peripheral lymph nodes were normal. He had a normal rectal temperature (38.2°).

Neurological exam:

Mental state: Alert, normal puppy.

Posture/gait: Normal.

Postural reactions: Normal proprioception, normal hemi walking and normal hopping on all four limbs.

Spinal reflexes: Anal reflex, patellar reflex, cranial tibial reflex, withdrawal reflex and panniculus reflex were all normal

Cranial nerves: menace response, palpebral reflex, facial and nasal sensation, jaw tone, pupillary light reflex (direct and indirect), physiological nystagmus, sense of smell, tongue and jaw movement and dazzle reflex were all normal. No pathological nystagmus or strabismus were observed.

Other: No pain on palpation of musculature, joints or column. Bumps his head in to the window on several occasions during the exam, which could indicate reduced sight, despite normal menace response.

Conclusion after examination: Normal physical exam and normal neurological exam (except might have reduced sight).

Neurological localization: Forebrain.

Case assessment I:

The presenting problem was cluster seizures approximately 3 weeks apart, with a normal neurological exam and normal behavior in between seizure episodes.

This in combination with the early onset seizures in this patient indicates an anomaly as the number one differential. Idiopathic or genetic epilepsy are next on the differentials list, although not typically presented at this early age.

Less likely differentials include; inflammatory or infectious brain disease. An inflammatory or infectious lesion would likely be more progressive over 3 months, but cannot be excluded at this stage.

Metabolic diseases such as hypoglycemia, hepatic encephalopathy and electrolyte abnormalities; metabolic disease was considered less likely due to normal clinical examination in between seizures and no correlation between seizures and feeding. Intracranial neoplasia is not common in puppies, but is also a possible differential.

Management I:

Initial diagnostic tests included a complete blood count (CBC) and biochemistry panel, to look for obvious metabolic reasons for the seizures.

Results: Table 1 and 2, abnormal results in bold.

Case assessment II:

The initial bloodwork was interpreted as normal, increased phosphorus in a young growing animal is usually physiological, and the mildly decreased HCT and HgB were interpreted as not significant. The main differentials after initial diagnostics were anomaly, idiopathic epilepsy and encephalitis.

Management II:

An MRI of the head was performed under general anesthesia to look for intracranial lesions and anomalies. The included sequences were, transverse and sagittal T2-weighted images, transverse and sagittal T1-weighted images pre-and post-contrast and a transverse FLAIR-sequence.

Premedication: Medetomidine (Cepetor CP Pharma) 0.015 mg/kg and methadone (Methadone, Norwegian Apothecary Union) 0.15 mg/kg intramuscularly.

Induction: Propofol (Propofol-Lipuro, Braun) in total 2.2 mg/kg intravenously, intubated with tube size 7.0 mm.

Maintenance: Isoflurane (IsoFlo, BGP Products) inhalation 2%, oxygen and air in 50/50 mixture.

Ringer's Acetate (Ringer-Acetate, Baxter) intravenously at 2mL/kg/hour.

The patient received intravenous contrast, gadodiamide (Omniscan, GE Healthcare) 0.2 mmol/kg.

The MRI showed a severe, bilateral enlargement of the lateral ventricles and associated attenuation of the brain parenchyma (Figure 1). The third ventricle and intrathalamic adhesion is poorly defined.

No abnormalities are noted associated with the aqueduct, fourth ventricle, cerebellum, and brainstem or included spinal cord. No abnormalities are noted in the orbits, ears or other peripheral structures.

D: Diagnostic study for congenital hydrocephalus affecting the lateral ventricles. A specifically treatable cause such as a mass lesion is not identified.

Diagnosis:

A diagnosis of congenital hydrocephalus was made from the MRI results.

Case assessment III:

A diagnosis of congenital hydrocephalus explained the patient's seizures, and no further diagnostic tests were performed in this case.

Management III

Due to financial restraints, and no accessible referral facilities offering hydrocephalus shunting surgery, the owner opted for medical management.

Initially the patient was treated with prednisolone (Prednisolon, Takeda) 0.5mg/kg BID and omeprazole (Omeprazol, Bluefish) 0.5mg/kg SID.

After 2 weeks the prednisolone was reduced to 0.5mg/kg SID.

At check up (by phone) after 40 days, the patient had been seizure free since the initial examination.

The prednisolone was then reduced to 0.5mg/kg EOD, and after a few days the dog started seizing again. The dosage was then increased to 0.5mg/kg SID. After this he remained seizure free. Further check up were performed at a clinic closer to the owner's home.

Discussion:

Hydrocephalus is one of the most common congenital malformations in domestic animals, especially in the dog. Hydrocephalus can be defined as an active distension of the ventricular system of the brain, related to inadequate passage of cerebrospinal fluid (CSF) from its point of production within the ventricular system to its point of absorption into the systemic circulation.

There are many different classifications of hydrocephalus: congenital/acquired, communicating/non-communicating, normotensive/hypertensive etc.

Communicating hydrocephalus is usually a bilateral and symmetrical dilation of the ventricular system without any detectable underlying macro- or microscopic lesion, resulting in a communication between the ventricular system and the subarachnoid space.

Non-communicating hydrocephalus is generally a result of complete or partial obstruction of normal CSF flow at any of the several critical stricture points within the intraventricular pathways or in the extra ventricular subarachnoid space. Examples are brain tumours, obstruction due to ependymitis/vasculitis (ex. feline corona virus).

A more correct classification might be intraventricular or extraventricular hydrocephalus, because there is reason to believe that also communicating hydrocephalus is a form of obstructive hydrocephalus.

Enlargement of the ventricles creates shear forces on the brain, predominantly in the periventricular white matter, which damages brain tissue and induces clinical signs.

Clinically hydrocephalus can be classified as congenital or acquired. There is poor correlation between ventricular size and clinical signs; the clinical signs are due to loss of neurons or neuronal function and/or alterations in intracranial pressure and its consequences. Breed predisposition for congenital hydrocephalus include Chihuahua, Maltese, Yorkshire terrier, English bulldog, Lhasa apso, Pomeranian, and Toy poodle, Cairn terrier, Boston terrier, Pug, Boxer, Shitzu and Pekingese. In these breeds the most commonly identified cause is stenosis of the mesencephalic aqueduct. However, in many cases an obvious point of obstruction is not identified. Other causes of congenital hydrocephalus are; intraventricular obstruction during a critical stage of development which later resolves, genetic or in utero exposure to infectious agents or teratogenic chemicals. The clinical signs can be focal or more diffuse signs of forebrain disease including; abnormal skull shape, ventral and/or lateral strabismus ("sunset gaze"), abnormal behaviour, cognitive dysfunction, ataxia, circling, blindness, seizures, disturbed consciousness and vestibular dysfunction. Affected patients can be smaller than the other puppies in the litter. Acquired hydrocephalus can develop at any age due to an underlying disease process.

Diagnosis is based on the clinical features and imaging of the brain. Previous diagnostic tests have now been replaced by non-invasive imaging using CT or MRI. Both modalities are useful for defining ventricular size, but MRI provides superior neural parenchymal resolution and is useful for the evaluation of infratentorial structures. In patients with an open fontanel, ultrasonography can be used to diagnose hydrocephalus, but will in most cases not identify an underlying cause. CSF analysis is helpful in cases of suspected inflammatory disease (meningoencephalitis).

Treatment can be either medical or surgical.

Medical treatment is used to delay surgery, to manage patients with acute deterioration, or when surgery is not an option. Glucocorticoids are often used to manage hydrocephalus, there are many protocols available but they all consist of a gradual tapering of the dosage and if possible; discontinued. Some patients can be effectively treated with chronic low-dose steroid therapy, however it's usually not a long-term treatment option. Acetazolamide and omeprazole are both used in managing hydrocephalus, but there is inconsistent effectiveness. Mannitol, hypertonic saline and furosemide can provide a temporary decrease in intracranial pressure and are reserved for emergency cases. Seizures can be treated with antiseizure medication if needed.

Surgical treatment consists of CSF shunting to the peritoneal cavity or less commonly, to the right atrium of the heart, and concurrent surgical correction of the underlying cause if possible. There are several shunt designs available, but they all consist of the same three components; a ventricular catheter, a one-way valve and a distal tube placed into the peritoneal cavity. The tubing is usually impregnated with barium to allow radiographic visualization. Both unilateral and bilateral shunting are described.

It is important to emphasize that not all patients with enlarged ventricles should undergo shunt surgery. Worsening of clinical signs which are unresponsive to medical treatment are the key factors when opting for surgical management. Contraindications for ventriculoperitoneal shunting are systemic infections, abdominal infections and skin infections at the site of one or both incisions. Also important; patients with severe thinning of the cerebral cortex are not good candidates for shunt placements as they have a very high risk of brain collapse and extra-axial haemorrhage at the time of insertion. There are several complications reported after shunt placement including; ventricular catheter migration, infections, shunt under drainage, kinking of the peritoneal catheter, valve fracture, skin necrosis, pain and over-shunting leading to subdural hematomas.

There are several studies in human- and veterinary medicine regarding ventriculoperitoneal shunting with varying results. Common for the veterinary publications are that shunting surgery is a good palliative treatment for dogs with hydrocephalus, but the overall prognosis is guarded. In humans, the overall failure rate is approximately 40% after 1 year and 50% after 2 years, and in a recent veterinary publication with 14 dogs the median survival time was 320 days (1-2340).

In conclusion, hydrocephalus is a common problem in our canine patients and can be managed both medically and surgically, but holds an overall guarded prognosis for long time survival. In our case, surgery was not an option for the owner do to financial restraints and the dog responded well to medical therapy. Ideally we should also have done CSF analysis, but again do to financial restraints and the MRI findings, this was not performed.

References:

- de Stefani, A., de Risio, L., Platt, S. R., Matiassek, L., Lujan-Feliu-Pascual, A., & Garosi, L. S. (2011, February 1). Surgical Technique, Postoperative Complications and Outcome in 14 Dogs Treated for Hydrocephalus by Ventriculoperitoneal Shunting. *Veterinary surgery*, 40(2), ss. 183-191.
- Gandini, G., Jaggy, A., Challande-Kathman, I., Bilzer, T., & Lombard, C. (2010). Cerebrum. I A. Jaggy, *Small Animal Neurology* (ss. 438-440). Hannover: Schlütersche Verlagsgesellschaft mbH & Co.
- Oevermann, A., Gorgas, D., Lang, J., Higgins, R., & Vandeveld, M. (u.d.). General neuropathology. *ESAVS Neuropathology of domestic animals* (ss. 35-36). Bern: ESAVS.
- Platt, S., & Bagley, R. S. (2014). Coma, stupor and mentation change. I S. Platt, & N. Olby, *BSAVA Manual of Canine and Feline Neurology* (ss. 145-148). Gloucester: British Small Animal Veterinary Association.
- Przyborowska, P., Adamiak, Z., Jaskolska, M., & Zhalniarovich, Y. (2013, February 1). Hydrocephalus in dogs: a review. *Veterinarni Medicina*, 58(2), ss. 73-80.
- Shihab, N., Davies, E., Kenny, P. J., Loderstedt, S., & Volk, H. A. (2011, June 1). Treatment of Hydrocephalus with Ventriculoperitoneal Shunting in Twelve Dogs. *Veterinary Surgery*, 40(4), ss. 477-484.
- Thomas, W. B. (2010, January 1). Hydrocephalus in Dogs and Cats. *Vet Clin Small Animal*, 40(1), ss. 143-159.

Tables:

1. Hematology:

Parameter		Result	Reference range
White bloodcell count	10e9/L	9.3	6.0-12.0
Red bloodcell count	10e12/L	5.51	5.5-8.5
Hemoglobin	g/dL	8.8	9.3-12.4
Hematocrit	%	38	44-57
Platelets	10e9/L	227	200-460
MCV	fL	69	60-77
MCH	pg	1.59	1.05-1.43
MCHC	g/L	23.1	19.2-22.3
RDW	%	14.0	14.0-17.0
MPV	fL	10.0	6.7-11.1
Lymphocytes	10e9/L	2.4	1.0-3.6
Monocytes	10e9/L	0.4	0.0-0.5
Granulocytes	10e9/L	6.5	3.0-10.0

2. Clinical biochemistry:

Parameter	Result	Reference range
ALB g/L	32	25-44
ALP U/L	88	20-150
ALT U/L	38	10-118
AMY U/L	491	200-1200
TBIL umol/L	7	2-10
BUN mmol/L	5	2.5-8.9
Ca mmol/L	2.71	2.15-2.95
PHOS mmol/L	2.79	0.94-2.13
CREA umol/L	65	27-124
GLU mmol/L	6.0	3.3-6.1
Na mmol/L	146	138-160
K+ mmol/L	4.5	3.7-5.8
TP g/L	57	54-82
GLOB g/L	25	23-52
CRP mg/L	15	<20

Figures:

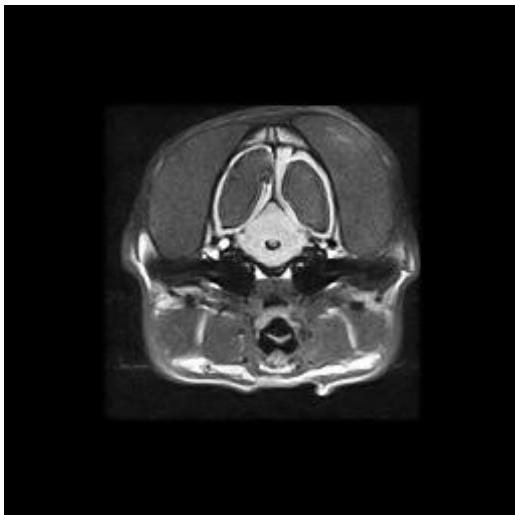


Figure 1. Transverse FLAIR images at the level of the lateral ventricles displaying severe, bilateral enlargement of the lateral ventricles (*) and associated attenuation of the brain parenchyma.