

Case Report Instructions EMSAVM / MASVM Oncology

General instructions

- Case reports, written in prose, must be in a problem-oriented approach and include a complete presentation of the case, illustrations where available and a short discussion of the case with the current literature with references. Candidates must demonstrate a comprehensive understanding of the topic with assessing all obtained diagnostic test results.
- A case report should contain 2000 words +/- 10%, excluding tables, references and appendix. Case reports > 2400 words will automatically be denied (0 points) or sent back for rewriting.
- Cases should demonstrate the width of experience of the Master student.
 - The cases must be exclusively from canine or feline patients and there must be at least 3 cases from each species and 10 cases in total.
 - The 10 cases must be a mixture of various neoplastic diseases (i.e. there should not be multiple cases of e.g. anal sac carcinoma). If the presentation and/or treatment are significantly different, two cases of the same neoplastic disease in different species are acceptable (e.g. one case of cutaneous lymphoma in dogs and one case of small cell hepatic lymphoma in cats).
 - Cases must be from different organ systems. If the presentation and/or treatment are significantly different, two cases from the same organ system in different species are acceptable (e.g. one case of splenic haemangiosarcoma dogs and one case of splenic mast cell tumour in cats; or e.g. one case of canine insulinoma and one case of feline thyroid carcinoma). As a guideline, the origin of the primary tumour determines the organ system. However, please pay attention that the main presenting complaints and/or paraneoplastic syndromes have enough variety (it is understood that non-specific clinical signs (e.g. lethargy, inappetence) are common in many cancer patients and this is of course acceptable).
 - At least four (4) cases should be treated with cytotoxic chemotherapy (other than corticosteroids).
 - Cases must be challenging enough to demonstrate the student's ability to work up and/or manage oncological cases of intermediate complexity. However, cases do not have to be unusual and/or "once in a life time" cases. Please bear in mind that cases that are too complex may not be reported adequately within the permitted word count (2000 words +/- 10%).
- Candidates are required to keep a table of the already submitted cases which shall be send with each new case report submission. The ESAVS Office will provide an Excel template for the table below:

Case Nr.	Species	Problem/s	Diagnosis
----------	---------	-----------	-----------

- Candidates are advised to submit cases shortly after beginning and throughout the program and not all cases at the end of the program.
- ESAVS cannot guarantee the evaluation of more than 3 case reports per semester. To ensure an evaluation in a specific semester, reports should be submitted no later than the given deadline for the respective semester (please see [Important Dates](#) on the ESAVS website).

Cases should be set out under the following headings:

- Title
- Signalement
- Case History and Physical Examination
- Case assessment including complete problem list, differential diagnosis with likelihood of what is possible for the case, tests performed and interpretation of these in relation to the case – do not use bullet points but write in prose
- Diagnosis
- Treatment (drugs need exact dosages) and adequate follow up
- Discussion of case in relation to current literature (please do not write a summary of the literature but discuss how the case fits or does not fit what is known about this neoplastic condition)
- References
- Appendix with laboratory results, cytologic images including report (if applicable) and diagnostic imaging pictures including interpretation (the examination board member reserves the right to see the original results (laboratory, diagnostic imaging) of selected cases).

Each case report is viewed by one member of the Examination Board and graded on a 0-20 scale (<10= fail, 10-11.9 = sufficient, 12-13.9 = fair, 14-15.9 = good, 16-17.9 = very good, 18-20 = excellent).

Evaluation of a case report

Step 1: Is the case report acceptable?

Is the case described in the report suitable at all?

Reasons to reject a case are:

- Please reread the general instructions for cases (see above)!
- A case is too simple (e.g. an obvious (skin) lesion followed by cytology & curative surgical resection)
- Lack of adequate state of the art clinical tests to arrive at a diagnosis (or at least a presumptive diagnosis). The case could be resubmitted when the lacking information can be retrieved.
- The animal's life was endangered by excessive/unnecessary diagnostic tests or treatments (including surgery). Such a case cannot be resubmitted.
- If the major treatments provided are not supported by evidence
- If the treatments were not state-of-the-art (e.g. radiotherapy of a nasal tumour without prior CT or MRI)
- If important diagnostic steps were not done because the clients did not want to do them or because of financial concerns.
- Diagnostic test reports not provided in English (e.g. pathology reports may have to be translated by the student to English)

- A case whose major problem does not fit within the specified master program. A cancer case, however, may have concurrent new or preexisting medical / cardiological / orthopaedic conditions, but if they are pertinent to the well-being of the dog, they should not be ignored. Yet, diagnosis and/or management of concurrent conditions that are non-related to the neoplastic disease should not constitute the majority of the case report.
- Most diagnostic tests and interpretation are done by someone else (e.g. referring veterinarian)
- Inadequate follow-up of case (e.g. diagnosis reached after euthanasia with no follow-up available)
- Multiple cases all with same problems or diagnosis (Please reread the general instructions for cases (see above))!
- Cases not seen during the enrollment in the program of the master student or where the master student is not the primary responsible clinician.
- More than 2400 words.

If a case is rejected the case report is assigned 0 points. The reason will be stated in the evaluation.

Step 2: Grading of the accepted case report

The case report will be evaluated based on a check sheet

An accepted case can reach a maximum of 20 points. A minimum of 10 points is required to pass.

The check sheet (see below) contains a list of 12 potential inadequacies. For each one the examiner can allocate a number of points. At the end a total number of points are given.

Recommendations for the candidate to avoid deduction of points:

- Make sure the history is sufficient (in an animal with PUPD, be sure to ask about amount of water that has been drunk; in an animal with vomiting or diarrhea, give information about details of these signs as well as the diet, etc. E.g. in an animal with a cutaneous mass report on the duration and growth rate according to the owners) If the animal has been pretreated by the referring vet, please comment on drug, dose duration and effect if possible.
- Give all details of the physical exam (report that rectal exam was done and normal in an animal with hypercalcaemia, etc. Comment on the severity of clinical signs (e.g. degree of lameness) if applicable)
- Reported tests need to be relevant for the animal and interpretation needs to be concise and also relevant.
- Do not just give a list of all potential differentials, but explain why a differential might be more or less likely (i.e. prioritize your differential list). Explain why you rule-out some differentials. Please provide specific differentials for specific signs (E.g. for a mass in the anal sac, please do not simply mention "cancer" as a differential diagnosis....) If you consider a clinical sign as non-specific (e.g. lethargy), please say so. For such signs a differential list may not be necessary or just a broad group of differentials could be provided (e.g. cardiac disease, cancer....).

- Assess your differentials and comment if they are likely related or unrelated (e.g. a dog with a mass in the anal sac and hypercalcaemia)
- Discuss your case – do not just repeat text book knowledge. If something has not been done or is abnormal and does not fit, try to explain this with pertinent literature.
- Show all results – missing graphics generally lead to points deducted.
- Treatment must be supported by evidence and state-of-the-art. This does not mean that the most effective treatment has to be provided in all cases (e.g. if you do not have radiotherapy in your country, you may justify giving a less established treatment alternative. However, you should mention, which treatments were recommended and what prognosis you have communicated to the client. Prognostic information should be specific in cases where specific information is available (e.g. 6 months' median survival time for splenic haemangiosarcoma treated adjuvantly with doxorubicin). If no specific information is available in the literature, please mention what estimate you have given the clients (e.g. up to 6 months or less than 4 weeks).
- Give information about therapy (including drug, dose (mg/kg or mg/m²), schedule, adverse effects) and outcome. Simple chemotherapy protocols can be summarized in the text especially if there are no significant adverse effects. More complex chemotherapy protocols and follow-up blood tests should be provided in the appendix in a table. Do not simply say "CHOP-protocol", but detail it in a table (including (if applicable) potential dose alterations (including the reasons), treatment delays, management of adverse effects).
- References must be peer-reviewed and in English. For general information about a neoplastic condition standard textbooks including the chapter and pages numbers may be sufficient. For specific data (e.g. prognosis for accelerated radiation therapy in feline squamous cell carcinoma of the nasal planum) the appropriate journal articles should be referenced. References should have a consistent format (e.g. Vancouver style).

Case Report Evaluation Check Sheet / Oncology

Grading Criteria:

For students who have enrolled in a Master of Advanced Studies in Veterinary Medicine (MASVM) or European Master of Small Animal Veterinary Medicine (EMSVM) program **before the winter semester 2024-2025**, the following grading criteria apply:

- The grades of the individual case reports are averaged to obtain one single grade. When this average grade is **below 10**, candidates are requested to resubmit revised versions of the failed case reports or new cases.
- A case report may not be acceptable and may be rejected if critical concerns in one (or several) areas result in a fail, regardless of whether all other required criteria are adequately met.

For students who have enrolled in a Master of Advanced Studies in Veterinary Medicine (MASVM) program for the first time **from the winter semester 2024-2025 onwards**, the following **new** grading criteria apply:

- 1. Pass = 10 points and more
- 2. Fail (case report insufficient) = below 10 points
 - modifications required - resubmission possible
 - case report insufficient - 0 points resubmission of this case report not possible - a new case report needs to be submitted
- **IMPORTANT:** the **average grade** for the module must be **13 points or higher** and none of the case reports must be graded below 10 points.
- A case report may not be acceptable and may be rejected if critical concerns in one (or several) areas result in a fail, regardless of whether all other required criteria are adequately met.

*The maximum grade of a case report is 20 points. The second column indicates the maximum number of points that can be reached.
In the third column the examiner indicates the number of achieved points, half points may also be allocated.*

	Maximum points	Allocated points
Complete signalment, history and physical examination <i>Comments:</i>	1	
Complete problem list <i>Comments:</i>	2	
Adequate differentials/ assessment for the problem list- the candidate tailors the differentials to this case and not every possible differential for each problem <i>Comments:</i>	2	
Adequate and/or appropriate tests (not too few or too many) <i>Comments:</i>	1	
Adequate assessment of test results (available results must be assessed for the submitted case) <i>Comments:</i>	1	
Diagnostic tests adequately graphically presented (radiographs, ECG, CT, <u>cytology</u> , endoscopy, etc. must be shown in adequate quality and size). <i>Comments:</i>	2	
Correct and/or justified diagnosis (incl. stage and grade if applicable) <i>Comments:</i>	2	
Adequate or appropriate therapeutic management including generic drug names and dosages; chemotherapy protocols <i>Comments:</i>	4	
Adequate follow-up for the case report to be meaningful <i>Comments:</i>	1	
Discussion pertaining to submitted case, adequately referenced <i>Comments:</i>	2	
Language and word count adequate <i>Comments:</i>	1	
Special features not covered above <i>Comments:</i>	1	
TOTAL POINTS/GRADE	20	

There is no “perfect” case and thus the subsequent example of a case should be viewed more as how to present your case. If you have questions, please ask them during one of the courses early on – the course masters are ready and willing to help.

Program: Master
program Case report number:
Date of submission:
4 Word count: 1882

Title: Chronic hematuria due to renal hemangioma

Signalment:

A 6 –year old, spayed female, Labrador retriever.

History:

The dog was referred for further investigations due to chronic hematuria that was first noted three months ago. The dog has pronounced discoloration (red/brown) of the urine daily and the color is most abnormal in the mornings. She does not have any pollakiuria, stragiuria or incontinence. She received antibiotics at the referring vet (Amoxicillin-clavulanic acid, Synulox® tabl. 20 mg/kg BID for 10 days), which did not have any effect on the symptoms. Antibiotics were stopped several weeks ago. The dog was current on vaccinations and had received deworming regularly. The dog did not have a travel history outside of Finland. The dog was spayed three years ago.

Physical examination:

The dog appeared bright and responded normally. Body condition was normal (Body condition score 3/5). Body temperature was normal (38,3° C). Mucous membranes were pink and moist and capillary refill time was normal (1,5 sec). Heart auscultation did not reveal abnormal findings: pulse rate was 120 beats / min, heart rhythm was regular and cardiac sounds were normal. Lung auscultation, respiratory rate (30/min) and respiratory type were normal. Lymph nodes were normal on palpation (mandibular 0,5 cm, prescapular 1,0 cm, popliteal 1,0 cm). Abdominal palpation and rectal exam were unremarkable. Rectal examination was unremarkable. No petechiae or ecchymoses were noted.

Case assessment I:

The main problem in this case was chronic red discoloration of urine.

Red discoloration of urine is most often hematuria, but may also be hemoglobinuria or myoglobinuria. All of these disorders make a positive reaction for blood on the dipstix, but true hematuria may be differentiated by looking at the urine sediment: In cases of hematuria, red blood cells can be found in the sediment.

Hematuria may originate from any part of the urinary tract as a result of disease process that causes damage to mucosa in the urinary tract or as a result of bleeding tendency. For the owner it may be

difficult to distinguish between hematuria and bleeding originating from the reproductive tract, so this needs to be evaluated also.

Bleeding due to a bleeding tendency may occur if there are problems in the primary coagulation (such as thrombocytopenia, vonWillebrandt factor deficiency) or in the secondary coagulation (such as congenital or acquired deficiencies in the coagulation factors).

Disease processes that lead to chronic hematuria in dogs include renal diseases (such as chronic degenerative renal diseases, chronic infections such as leptospirosis or pyelonephritis, renal calculi as well as benign or malignant renal tumors or idiopathic renal hematuria), diseases in the urinary bladder (such as urinary calculi, benign and malignant bladder wall changes and bacterial infections) and urethra (such as calculi and benign and malignant tumors). Chronic hematuria originating from ureters is very rare, but may be possible in cases of calculi or tumors in this area.

Bloody discoloration of the urine, noted by the owner, may also arise from vagina or uterus as a result of benign or malignant tumors, hormonal disturbances or infectious processes in female dogs. Since this dog was spayed vaginal tumors and bleeding from the uterine stump need to be considered. Bleeding from the uterine stump most often results from ovarian remnants.

Management I:

Initial diagnostic tests include vaginoscopy, complete blood count (CBC), coagulation parameters, serum biochemistry, urine analysis and culture as well as abdominal ultrasound examination.

Results: Table 1-3

Pictures 1

Report 1-2

Case assessment II:

Urine analysis confirmed the presence of hematuria. Since hematology was normal, the amount of blood in the urine was not large enough to cause anemia. Coagulation abnormalities were ruled out as an underlying disease and since vaginoscopy was normal the hematuria was confirmed to originate from the urinary tract.

A structural change was identified cranially in the medulla of the right kidney (size 1,6x1,9 cm). Possible differential diagnoses included malignant or benign acquired lesion or a congenital lesion. The connection of this lesion to patient's hematuria was unclear at this point. No other abnormalities were noticed in the abdominal ultrasound examination, ruling out many of the possible other causes for hematuria: Renal and bladder calculi would have been noticed in the examination as well as advanced bladder wall changes. Very early neoplastic changes in bladder wall might be left unrecognized. Urine analysis did not reveal other abnormalities than hematuria, ruling out chronic bacterial cystitis. Urethra cannot be visualized in abdominal ultrasound examination and further exams are warranted to examine the urethra (such as retrograde contrast studies or cystoscopy).

Since it was unclear whether the lesion in the right kidney was causing the symptoms, and removal of the kidney for histopathology is very invasive, a cystoscopy was scheduled to confirm the origin of the hematuria.

Management II:

The dog was pre-medicated with butorphanol 0,2 mg/kg iv. (Butordol® 10 mg/ml), the anesthesia was induced with propofol 4 mg/kg iv. (Propovet® 10 mg/ml) and maintained after intubation with inhaled sevoflurane. The perineal area was clipped and surgically scrubbed. Cystoscopy was performed with a 4,5 mm flexible endoscope (Olympus®).

Results: Report 3

Pictures 2

Case assessment III:

Cystoscopy did not identify lesions in the bladder wall or urethra that would explain the chronic hematuria. Both urethral openings were located more caudally than normally at the level of the urethral sphincter. During cystoscopy it was noted, that brown urine was flowing from the right ureter, indicating that hematuria might be originating from the right kidney.

Ultrasound examination of the right kidney had revealed a mass-lesion in the right kidney. Differential diagnoses at this point included a renal hemangiosarcoma, other renal malignancies and renal hemangioma. Surgery was scheduled for removal of the kidney and histopathological examination. Fine needle aspirated were discussed with the owner prior to surgery, but a decision was made to proceed to nephrectomy.

Management III:

The dog was premedicated with methadone 0,2 mg/kg iv (L-Polamivet® 2,5 mg/ml) and anesthesia was induced with midazolam 0,2 mg/kg iv (Midatzolam® 5 mg/ml) and propofol 4 mg/kg iv (Propovet® 10 mg/ml). Anesthesia was maintained with inhaled isoflurane and a fentanyl (Fentanyl® 50 ug/ml inj.) 20 ug/kg/h infusion. Mechanic ventilation was used during anesthesia. Dog received iv-fluids during and 24 hours after the surgery (Ringer's lactate® 2 x maintenance requirement). Pain was controlled post operatively with a fentanyl patch (Durogesic® 75 ug/h) for four days and peroral tramadol 2 mg/kg BID-TID (Tramal® 50 mg tabl) as needed for 2-3 days. The dog was kept in the ICU for surveillance overnight after the operation. Recovery from surgery was uneventful.

Results: Report 3

Diagnosis:

Chronic hematuria due to a renal hemangioma.

Treatment:

The changed kidney was surgically removed.

Follow up:

The dog did not return to our clinic for controls, but was controlled later at the referring veterinarian. The dog recovered unevenfully and the hematuria did not occur after surgery.

Discussion:

Primary renal neoplasia is rare in dogs and they represent approximately 0,7-2,5% of all canine tumors. Metastatic renal tumors occur more commonly. Of primary renal tumors renal cell carcinoma was most common (69%) followed by transitional cell carcinoma (9%), adenoma and papilloma (7%), sarcoma (7%), nephroblastoma (4%), fibroma (2%) and lymphoma (2%). Most renal tumors (>85%) are malignant and a benign renal hemangioma is an uncommon neoplasm in the dog. Benign renal tumor are considered of limited clinical relevance and are often encountered as incidental findings at necropsy. Chronic hematuria due to a renal hemangioma has been described previously in a few case reports.

The dog in the current case was a typical presentation of renal hematuria. The lack of signs suggestive of a lower urinary tract problem such as pollakiuria or strangiuria make renal hematuria or hematuria due to a coagulopathy likely. Apart from renal neoplasia, renal hematuria may be caused by renal teleangiectasia, idiopathic renal hematuria, polycystic renal disease, renal calculi, renal infarction, glomerular diseases, Leptospirosis and pyelonephritis. In the present case cystoscopy provided important information localizing the hematuria to the right kidney. Additionally a urine sample could've been obtained during cystoscopy from the right ureter for culture and cytology. In this case renal ultrasonography was able to identify a lesion suggestive of a renal neoplasia.

Decision to remove the entire kidney was made based on the fact that most renal tumors are malignant. Knowing that the change was a benign hemangioma, other options could've been taken into account such as nephron sparing surgical procedures.

References:

- Forrester SD. Diagnostic approach to hematuria in dogs and cats. *Vet Clin North Am Small Anim Pract.* 2004 Jul;34(4):849-66.
- Lee R, Weaver AD, Robinson PB. Persistent haematuria in a dog due to a discrete renal haemangioma. *J Small Anim Pract.* 1974 Oct;15(10):621-6.
- Widmer WR, Carlton WW. Persistent hematuria in a dog with renal hemangioma. *J Am Vet Med Assoc.* 1990 Jul 15;197(2):237-9. PubMed PMID: 2384325.
- Mott JC, McNulty JF, Darien DL, Steinberg H. Nephron sparing by partial median nephrectomy for treatment of renal hemangioma in a dog. *J Am Vet Med Assoc.* 1996 Apr 15;208(8):1274-6.
- Eddlestone S, Taboada J, Senior D, Paulsen DB. Renal haemangioma in a dog. *J Small Anim Pract.* 1999 Mar;40(3):132-5.

Tables:

1. Hematology

Parameter	Results	Unit	Reference range
White blood cell count	5,54	cells 10 ⁹ /l	5,4-17,4
Segmented neutrophils	3,13	cells 10 ⁹ /l	2,9-13,8
Band neutrophils	0	cells 10 ⁹ /l	0
Monocytes	0,47	cells 10 ⁹ /l	0,1-1,1
Lymphocytes	1,72	cells 10 ⁹ /l	1,0-5,4
Eosinophils	0,22	cells 10 ⁹ /l	0,1-1,5
Basophils	0	cells 10 ⁹ /l	0
Hematocrit	54,6	%	38-57
Hemoglobin	188	g/l	140-203
Red blood cells	8,35	cells 10 ¹² /l	5,3-8,0
MCV	67,3	fl	67-80
MCH	24,5	pg	24-29
MCHC	345	g/l	345-367
Platelets	307	cells 10 ⁹ /l	102-395

2. Clinical biochemistry

Parameter	Result	Unit	Reference range
Alkaline phosphatase (Afos)	73	U/l	33-215
Alkaline aminotransferase (Alat)	32	U/l	18-77
Albumin	32	g/l	30-41
Bilirubin	2,9	umol/l	2,5-8,5
Glucose	5,9	mmol/l	4,0-6,4
Potassium	4,6	mmol/l	4,2-5,4
Calcium	2,7	mmol/l	2,3-3,0
Cholesterol	6,9	mmol/l	3,7-9,8

Creatinine	102	umol/l	57-116
Sodium	153	mmol/l	147-157
Total protein	58	g/l	58-77
Urea	5,8	mmol/l	2,4-8,8

3. Urine analysis

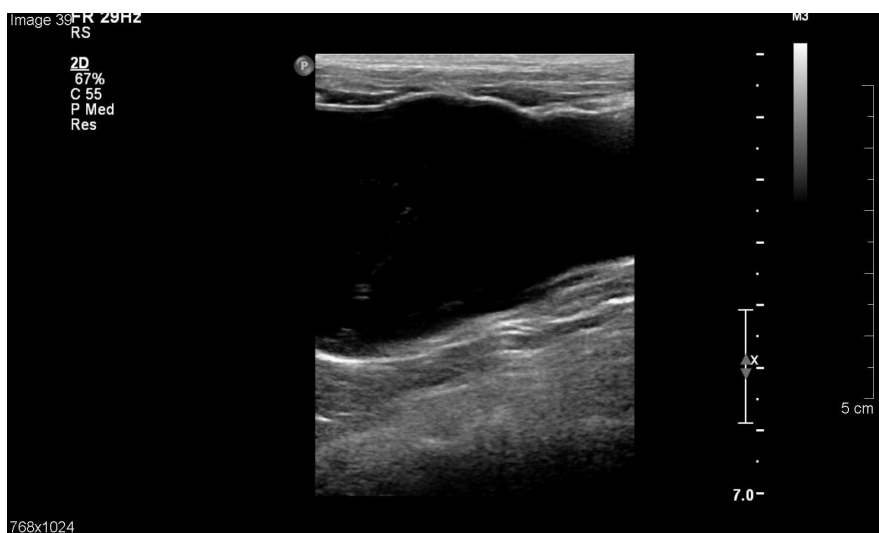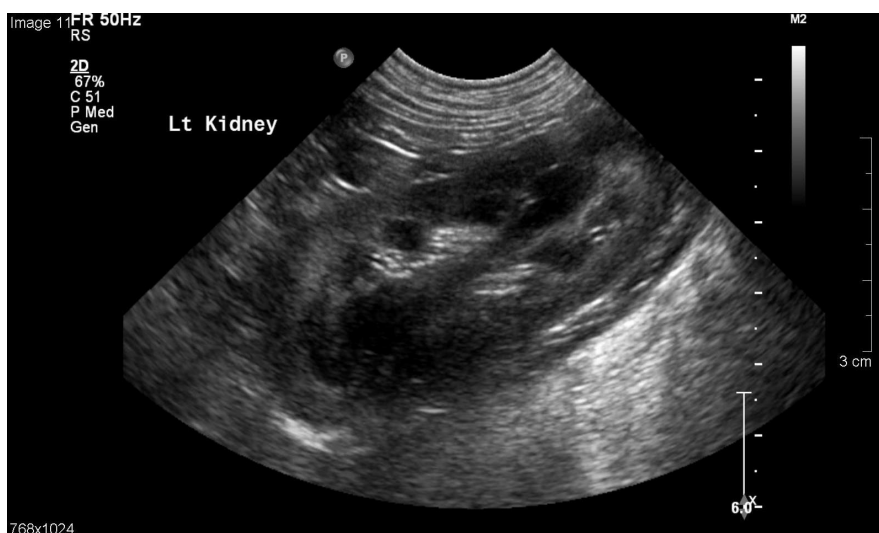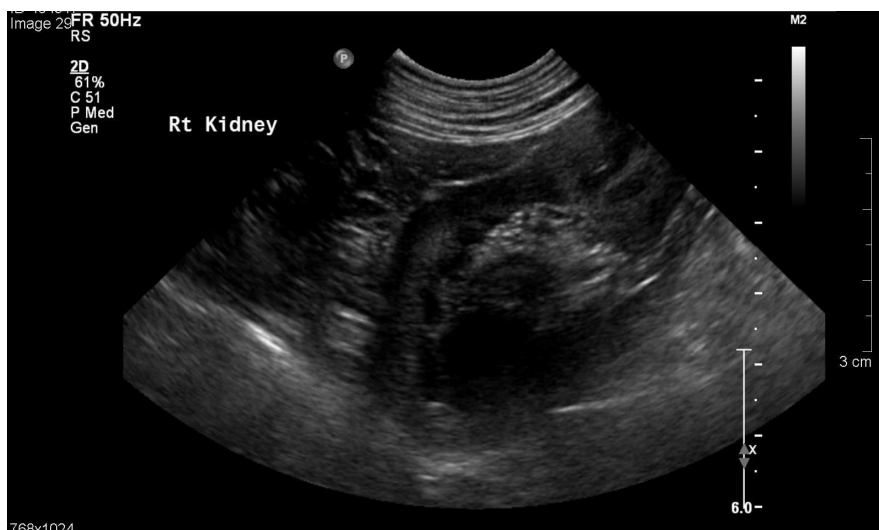Parameter	Result
Bilir	++
Gluk	0
Ket	0
Sg.	1,041
pH	5,5
Prot	++
Blood	+++
Aerobic culture	Negative
Mycoplasma culture	Negative
Sediment	Erytr >100/hpf, Leuk 0-3/hpf, epithelial cells 1-3/hpf

4. Coagulation parameters

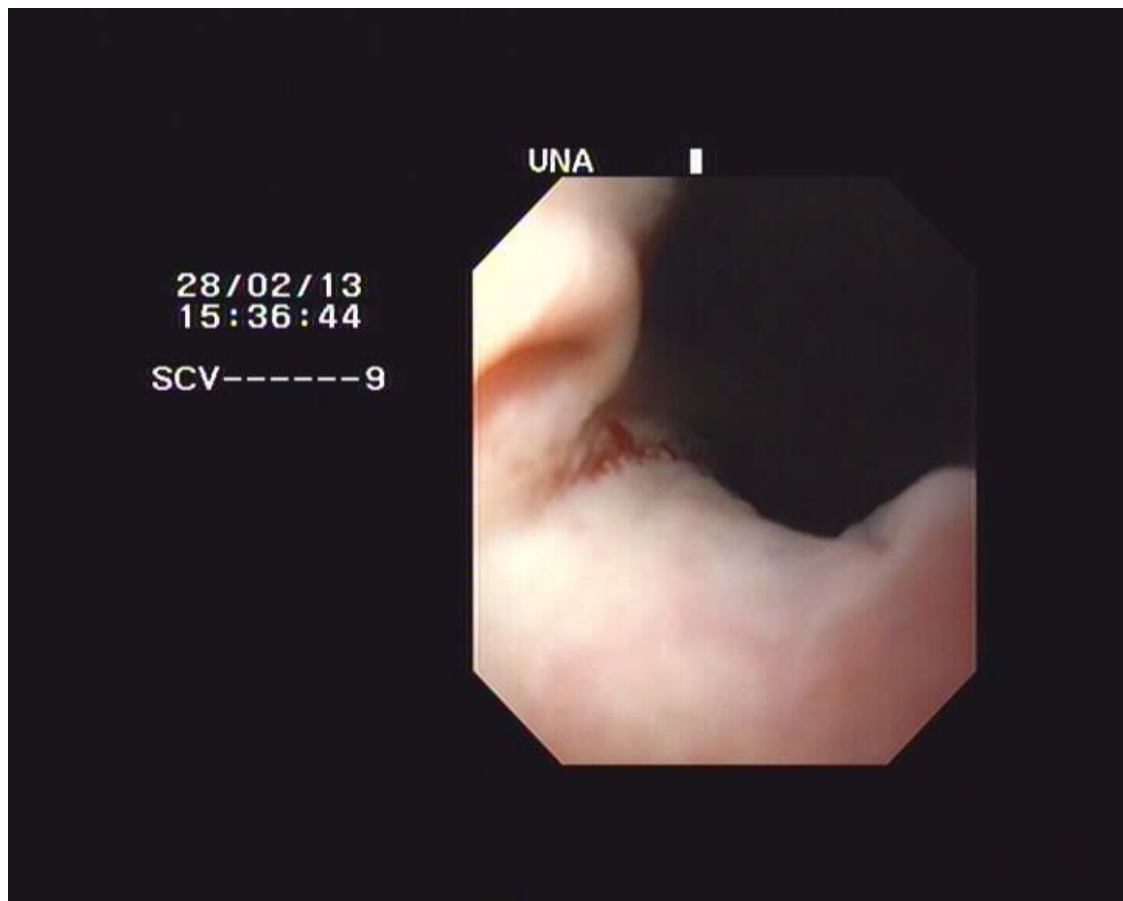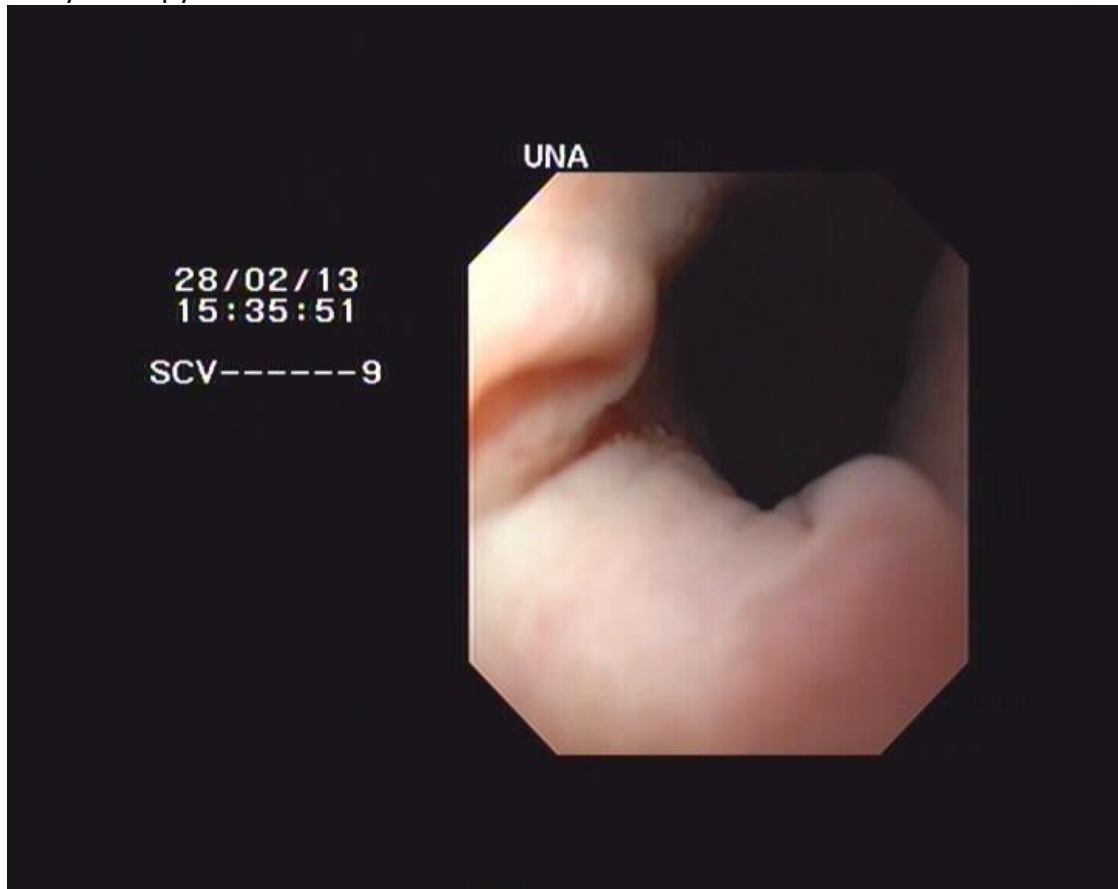
Parameter	Result	Unit	Reference range
PT	15,3	sec	<23
aPTT	8,1	sec	<16,4
D-dimer	0,2	mg/l	<0,3
BMBT	2	min	< 4

Pictures:

1. Abdominal ultrasound examination



2. Cystoscopy





Reports:

1. Vaginoscopy

Normal. No masses, no secretions.

2. Abdominal ultrasound examination

In the cranial part of the medulla in the right kidney, there is a round heterogenic mass-like lesion (1,6x1,9 cm). Left kidney normal. Liver, spleen, intestine, lymph nodes normal. Small amount of sediment in the urinary bladder, bladder wall normal.

3. Cystoscopy

Vagina, urethra normal. Both ureters located more caudally than normal, at the sphincter area. Brown discolored urine flowing from the right ureter. Bladder wall normal.

4. Histopathology

Two symmetrical renal halves submitted. There is a brown, soft, fragile mass (coagulated blood) occluding the pelvis. Adjacent to the renal pelvis there is a well demarcated multitubular mass with dark red cut surface. Mass is composed of dilated blood filled spaces, no features of malignancy. Histology is consistent with a completely excised renal hemangioma.



Master Program ESAVS

Case report number 1

Word count: 2200

Insulinoma in a dog

Signalement:

A 14 years 10 months old, Spayed Female, 6.7 kg, Shih Tzu.

History:

The dog was presented for having seizure earlier during the day. No previous history of seizure activity was reported; only occasional twitching maybe noticed over the past 6 months. Appetite was reported as possibly decreased over the past few days but no vomiting nor diarrhoea had been noticed. Urination was reported as normal. The dog was a 100 % indoors animal and no exposure to toxics or poison was reported as possible. The dog was not vaccinated, not dewormed and not under any kind of Heartworm/ Tick prevention. Owner could not provide a clear description of the seizure episode witnessed but mentioned that the dog suddenly fell unconscious, non responsive, had been paddling and salivating until she recovered few minutes after.

Physical examination:

The dog was conscious and responsive, showing mild twitching but no overt seizure activity at the time of presentation. Body temperature was normal (38.2 C). Mucous membrane were pink, capillary refill time normal (< 2 sec), hydration status was adequate. Heart rate was 130, Respiratory rate 28, spO2 91 %. The chest auscultation was clear (no heart murmur audible) and abdomen was smooth with a normal palpation. Neurological exam was totally normal. So was the rest of the physical examination, including vision.

Case Assessment I:

The major problem was sudden onset of seizure activity .

From the description given by the owner, it was thought to be more likely real seizure activity (isolated, generalised seizures) rather than a syncopic episode or other paroxysmal events; but those could not totally be excluded at that stage.

Minor problems were mild muscle twitching described over the past 6 months and decreased appetite noticed over the past few days; but they were thought to be possibly related to the disease causing the seizures.

Seizure disorders can be idiopathic or of intracranial or extra cranial origin.

Intracranial causes of seizures include congenital malformation, hydrocephalus, lissencephaly, neoplasia (primary brain tumour versus metastatic disease), inflammatory disease, infectious disease, granulomatous meningoencephalitis, necrotizing encephalitis, vascular disease, haemorrhage, infarct, metabolic storage diseases or degenerative conditions.

Extra cranial causes of seizures include toxins, metabolic diseases, hypoglycaemia, liver disease, hypocalcaemia, hyperliproteinemia, hyper viscosity, electrolytes disturbances, hyperosmolarity or severe uraemia.

Given the age of the animal, the clinical exam, and the history, congenital malformation, hydrocephalus, as well as toxic origin was ruled out.

**Management I:**

Initial diagnostic tests included full CBC, biochemistry profile as well as a Heartworm/E Canis Snap test. Bladder was empty and no urine sample could be obtained initially.

Results: Table 1-2.

As the dog restarted seizing, an IV catheter has been set up and the dog was given Diazepam IV (0.5 mg/kg) as well as a Dextrose bolus IV (2 ml Dextrose 50% in 3 ml saline); which controlled the episode.

Assessment II:

Additional problems were elevation of Haematocrit, mild leukopenia (but not confirmed on blood smear), Hypoglycaemia, hypophosphatemia, mild hyperproteinemia with hyperglobulinemia, and mild elevation of Alanine Aminotransferase (ALT).

The elevation of Haematocrit with a high normal Red Blood Cell count and Haemoglobin concentration suggests mild polycythaemia. Polycythaemia can be absolute (primary (polycythaemia Vera) or secondary (in response to increased secretion of erythropoietin which can happen with hypoxia or with renal tumours)) or relative.

Leukopenia can be seen with viral disease, massive infection, endogenous toxemia, SLE, Leishmaniose, anaphylaxis or bone marrow neoplasia.

Hypoglycaemia can be associated with either:

- Excess secretion of insulin or insulin-like factors (insulinoma, extra pancreatic tumour or islet cell hyperplasia),
- Decreased glucose production (hypoadrenocorticism, hypopituitarism, growth hormone deficiency, liver diseases, glycogen storage diseases, neonates, and toy breeds)
- Excess glucose consumption (sepsis or extreme exercise)
- Drugs administration (insulin or oral hypoglycemics, salicylates (aspirin), acetaminophen, beta-blockers, beta-2-agonists, ethanol, monoamine oxidase inhibitors, tricyclic antidepressants, ACEs inhibitors, antibiotics (tetracyclines), lidocaine overdose and lithium.
- Fasting, malnutrition or pregnancy
- Spurious causes.

Hypophosphatemia can be seen with endocrine disorders (primary hyperparathyroidism, diabetic ketoacidosis, hyperinsulinism), puerperal tetany, hypercalcemia of malignancy, respiratory alkalosis and renal tubular defects (Fanconi syndrome).

The elevation of plasma total protein was attributed to the mild elevation of Globulins (Albumin level normal). Causes of hyperglobulinemia can be separated in causes of polyclonal gammopathy (infections, immune mediated diseases, neoplasia) or monoclonal gammopathy (neoplasia).



Elevation of ALT was unlikely to be related to false measurement as no lipaemia nor haemolysis was present. It can be seen after the administration of hepatotoxic drugs and glucocorticoids or in relation to liver disease.

Since the haematocrit was only moderately elevated with other parameters (RBC count/HGB) still within normal range, polycythaemia was thought to be more likely relative and secondary to possible mild sub clinical dehydration; the mild elevation of Total Protein being possibly related.

As the mild leukopenia was not reflected on the blood smear and in the absence of azotaemia or clinical signs that would suggest systemic infection, it was thought to be of little significance though previous infection with Canine Distemper Virus could not be ruled out on a non vaccinated dog. No viral inclusions were seen on the blood smear.

The major finding that could possibly explain the seizures present was hypoglycaemia. Given the signalement and the history (no treatment given, no exercise reported, good body condition, spayed female), all neonate, toy breed, drug induced condition as well as malnutrition, hypopituitarism, growth hormone deficiency and pregnancy could be ruled out.

In absence of gastrointestinal signs, hypovolemic shock, electrolytes disturbances, anaemia and lymphocytosis, hypoadrenocorticism was considered as very unlikely. The absence of left shift made excessive glucose consumption because of sepsis unlikely too.

In the presence of elevation of ALT, liver disease could not be ruled.

Excessive insulin or insulin like factors production was considered as possible; especially with the hypophosphatemia noted.

As the dog's appetite has been reported as decreased over the past few days, hypoglycaemia secondary to fasting could not be ruled out.

Finally, most intracranial cause of seizures (neoplasia, GME, NE, vascular disease, infarct, inflammatory or degenerative condition) were still possible as well as idiopathic seizures.

Management II

The dog was admitted in hospital for IV fluid therapy, seizures watch and blood glucose monitoring overnight (every 2 hours initially, every 4 hours if stable). Ideally a urine sample was to be collected prior to start with Lactate Ringer infusion at 30-ml/ hr.; but bladder was empty and cystocentesis unsuccessful. Urinalysis was performed the next day only (see table 3).

A/d food was offered and the dog was eating ravenously.

Glucose curve (see Table 4) showed persistent hypoglycaemia despite Glucose bolus given and then 7.5 % Dextrose added to the LRS CRI.

The dog had one more seizure episode, which necessitated one IV Phenobarbitone injection (5 mg/kg over 5 minutes), as seizure was persistent despite Diazepam and Glucose administration. Dog has been stable and did not require any further treatment thereafter.

PCV/TP/smear/ Electrolytes and Phosphate were repeated the next day. Blood Glucose continued to be monitored every 2 hours.



Fluids were supplemented according to results with 10 then later 15 % of Dextrose added; and 20 mEq/L of KCl.

Food (a/d) was offered every 2 hours.

Assessment III

As seizure activity settled down without requiring further more antiepileptic drugs once the blood glucose had been maintained within normal range, it appeared that the persistent hypoglycaemia was the more likely cause of the seizures noted and intracranial causes were therefore considered less likely.

As the dog was eating very well, was bright, not vomiting, showed no PUPD, and had only a mild elevation of ALT, other liver enzymes being normal, liver disease seemed less likely too.

No evidence of sepsis had been identified.

Therefore the refractory hypoglycaemia noted was thought to be possibly secondary to excessive secretion of insulin or insulin-like factors.

Management III

The dog was fasted for few hours with her Blood Glucose still monitored every 2 hours. As soon as hypoglycaemia was noted a blood sample was taken for measurement of insulin concentration and the dog was then fed again every 2 hours.

Result: Table 5.

The dog was sedated with IV Medetomidine/ Torbugesic to image. Thoracic and abdominal radiographs as well as abdominal Ultrasound were performed. See images and reports 1-2.

In the absence of other likely causes of the inappropriate insulin secretion, a diagnosis of insulinoma was made.

Given the several abnormalities noted on the abdominal ultrasound, it was thought to be possibly stage 2-3 disease already.

An exploratory laparotomy was advised in order to assess pancreas fully and consider pancreatic mass / gross metastases resection if identified and possible. Biopsies could be taken to confirm diagnosis in case of non-resectable tumour.

Owner declined surgery because of the age of the animal and for cost reason.

Medical treatment was then started with Prednisolone at 0.5 mg/kg/day PO and Diazoxide, initially at 10 mg/kg/day divided tid increasing gradually to 40 mg/kg /day divided tid as required.

Diet modifications were made as well, feeding the dog small frequent meals (every 4 to 6 hours) of preferably a diet high on proteins, fat and complex carbohydrates. Warnings were given to owner about possible acute hypoglycaemic crisis: glucose water or honey to be administered if any weakness noted in between meals.



The dog was rechecked 1 week after initiation of treatment, and then 2 weeks after the Diazoxide dose was built up. Blood glucose measurement 6 h after Diazoxide administration was still recorded low (1.4- 1,7 mmol/L), so dose of prednisolone has been increased to 1 mg/kg/day.

The blood glucose was still low (1.7 mmol/L) with this dosage, so Diazoxide dose has been increased to 22 mg/kg/day divided tid (50 mg Eudemine tablet tid).

The dog has been rechecked and blood glucose monitored every 2 weeks at first then monthly since it was stable.

So far, (14 months after the diagnosis of insulinoma was made), the dog is still doing fine.

Discussion

Seizures and muscle twitching are commonly reported in dogs with insulinoma. The most typical laboratory abnormality is hypoglycaemia with concurrent hyperinsulinemia. The identification of a pancreatic mass with imaging studies strengthens the suspicion but most insulinomas are small (<4cm in diameter) and preoperative identification is difficult. A negative scan does not rule out the presence of a tumour. Ideally, an exploratory laparotomy is advised to allow visualisation of the pancreas, identification of macroscopic metastasis and if possible the resection (or at least debulking) of the tumour(s). The diagnosis is confirmed with histologic examination and immunohistochemical staining of the pancreatic mass.

Medical treatment is indicated prior to surgery, post operatively if needed and in dogs in which surgery is not performed like in our case. Medical therapy can be divided into cytotoxic treatment directed at destroying insulin secreting beta cells (Streptozocin; but is nephrotoxic) versus treatment aimed at relieving hypoglycaemia (dietary modification, prednisolone, diazoxide, or synthetic somatostatin).

The long-term prognosis for dogs with insulinoma is grave. The mean survival time for medically managed patient is reported as 12 months, from onset of signs of hypoglycaemia.

References

- Richard W. Nelson. Disorders of the Endocrine Pancreas. In Nelson RW, Couto CG, Eds Small Animal Internal Medicine, Second edition. Mosby Inc, 1998:735-737; 766-771.
- Michael Podell. Seizures. In Ettinger SJ, Feldman EC, Eds, Textbook of Veterinary Internal Medicine, Seventh edition. W.B.Saunders Company, 2010: 228-230.
- Rebecca S. Hess. Insulin –Secreting Islet Cell Neoplasia. In Ettinger SJ, Feldman EC, Eds, Textbook of Veterinary internal Medicine, Seventh edition. WB Saunders Company, 2010:1779-1782.
- Kenneth W. Simpson and Audrey Cook. Hypoglycaemia. In AG Torrance, C.T.Mooney, BSAVA Manual of Small Animal Endocrinology, Second Edition, 1998:141-149.

Tables

1. Haematology



Parameters	Day 1	Day 2	Reference Range
RBC (X10.12)	8.4		5.5-8.5
HCT %	59.9	Manual PCV 54	37-55
HGB g/dL	18.0		12-18
MCV fL	71.0		60-77
MCH pg	21.31		18.5-30
MCHC g/dL	30.0		30-37.5
RDW %	16.1		14.7-17.9
% Reticulocytes	0.9		
Retics K/uL	73.1		
WBC (x10.9/L)	5.32		5.5-16.9
Neutros (x10.9/L)	3.81		2-12
Lymphs (x10.9/L)	0.88		0.5-4.9
Monos (x10.9/L)	0.44		0.3-2
Eos(x10.9/L)	0.16		0.1-1.49
Baso (x10.9/L)	0.03		0-0.1
PLT (k/uL)	423		175-500
MPV fL	7.57		
PDW %	16.5		
PCT %	0.3		

E Canis	-VE		
HTW	-VE		

2.Clinical Biochemistry

Parameter	Day 1	Day 2	Reference range
ALB (g/L)	35		22-39
ALKP (U/L)	84		23-212
ALT (U/L)	105		10-100
AMYL (U/L)	737		500-1500
BUN/UREA(mmol/L)	8.1		2.5-9.6
Ca (mmol/L)	2.90		1.98-3
CHOL(mmol/L)	4.40		2.84-8.27
CREA (umol/L)	77		44-159
GLU (mmol/L)	2.33		3.89-7.94
PHOS (mmol/L)	0.24	0.96	0.81-2.19
TBIL (umol/L)	6		0-15
TP (g/L)	83	70	52-82



GLOB (g/L)	48		25-45
Chloride (mmol/L)	118	116	109-122
Potassium (mmol/L)	4.1	3.1	3.5-5.8
Sodium (mmol/L)	159	154	144-160

3. Urinalysis

Parameter	Day 2
Source	Cystocentesis
Colour	Yellow
Turbidity	Clear
Specific Gravity	1.038
PH	6
Protein	+
Glucose	-
Ketones	-
Bilirubin	-
Blood	+++
Leucocytes phf	0
Erythrocytes phf	5
Epithelial cells	Few
Crystals	+Calcium Oxalate
Bacteria	None (plated, no growth)

4. Glucose curve -first 12 hours post admission

	22h	24h	2h	4h	6h	8h	10h	12h	Reference range
BG(mmol/L)	2.33	3.5	1.6	2.2	3.3	2.9	1.4	2.4	3.89-7.95

5. Insulin assay

Result	Reference range
>70 umol/L (Sample taken when hypoglycaemia present)	<20umol/L

Reports:

1. Radiology

Liver, spleen and kidneys appear normal. Numerous bladder stones are present. Some stools are present in colon. VD view suggests severe hip dysplasia / DJD
Dx: Bladder stone/ Hip DJD

2. Abdominal Ultrasound

The left adrenal gland is markedly enlarged to a diameter of >1 cm and is hypoechoic. It has the classic peanut shape but has some mixed echogenicity and a slightly bulbous appearance. This might be a tumour. The right adrenal looks normal but is borderline enlarged at 7.8 mm. Also can see some calcifications in the left kidney, numerous large stones in the bladder. The cranial mesenteric lymph nodes are prominent, hypoechoic and measure 6 mm diameter.

Rest of the examination is unremarkable. Examination of the pancreas did not reveal any visible mass.

D: possible adrenal tumour and mesenteric lymph node involvement. No mass visualised in pancreas area.



